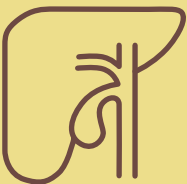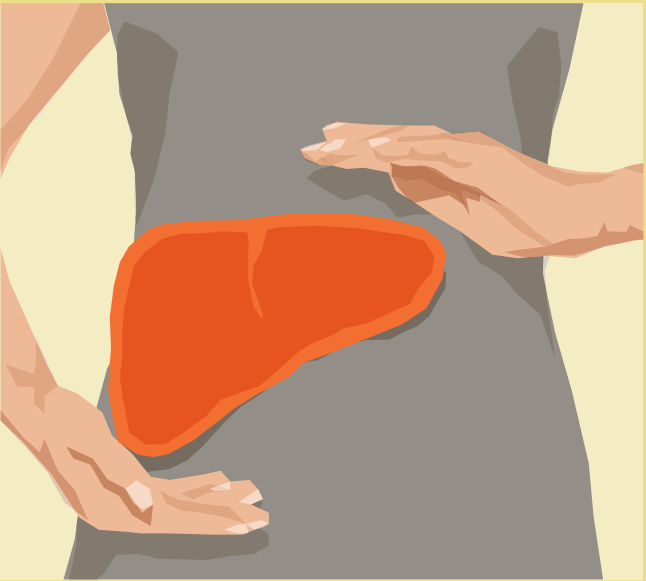


Primary biliary cholangitis (PBC)



Publisher

FALK FOUNDATION e.V.



Leinenweberstr. 5
79108 Freiburg
Germany

www.falkfoundation.org

© 2019 Falk Foundation e.V.
All rights reserved.

1st edition 2019

Primary biliary cholangitis (PBC)

Compiled by
Prof. Dr. Thomas Berg and
Toni Herta, Leipzig

Acknowledgement

We are grateful to the author of the previous edition of this booklet, Prof. Dr. Ulrich Leuschner, Praxisklinik für Gastroenterologie, Frankfurt am Main, Germany.

Address of the authors

Prof. Dr. Thomas Berg
Toni Herta
Sektion Hepatologie
Klinik und Poliklinik für Gastroenterologie
Universitätsklinikum Leipzig
Liebigstr. 20
04103 Leipzig
Germany

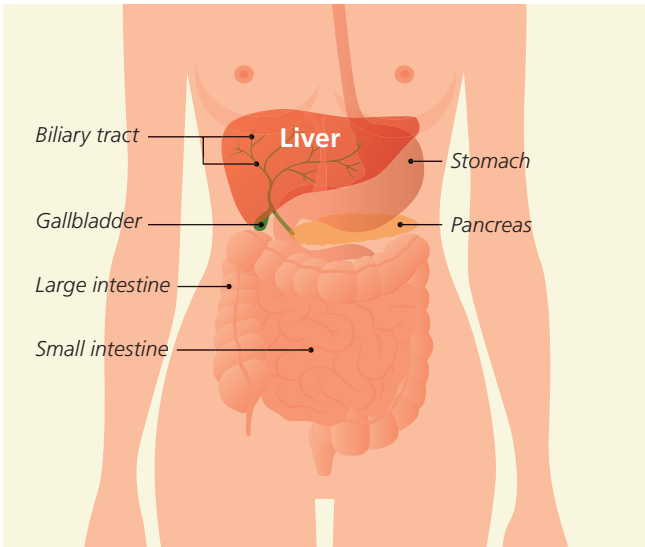
The liver	4
Structure and function	5
What is primary biliary cholangitis?	8
How common is the disease?	9
Does PBC shorten life expectancy?	9
What are the signs of PBC?	10
How do doctors diagnose PBC?	12
What are the main physical signs of PBC?	12
Which blood tests are necessary?	13
What can be detected by ultrasound?	15
Does a liver biopsy need to be taken?	16
Can genetic testing help predict PBC?	16
How does PBC progress?	17
What other conditions are typically associated with PBC?	18
What is cirrhosis of the liver and what are its implications?	20
Are PBC patients at a higher risk of cancer?	22
How is PBC treated?	23
Which medications are used to treat PBC?	23
How can the symptoms of the disease be reduced?	26
When is liver transplantation required?	28
What is a PBC overlap or variant syndrome?	30
Summary	31

The liver

The liver is made up of several different lobes: a larger right lobe, a smaller left lobe, and two other even smaller lobes (the quadrate and caudate lobes). It can also be subdivided into eight segments. The liver is located in the right upper quadrant of the abdomen, directly below the diaphragm and the bottom of the rib cage, which makes it difficult to feel by hand. It is surrounded by a capsule of connective tissue.

The liver is the largest and most complex metabolic organ in the body, weighing 1.5–2 kilograms and carrying out more than 500 different functions. It typically holds about 10% of the total volume of blood in the body, and up to 1.4 liters of blood are pumped through it each minute, which requires extraordinary filtering capabilities. The liver is thus the main organ in the body for storage, detoxification, and excretion, which is why it also plays an important role in breaking down alcohol and medications. It is also important for metabolizing proteins, fats, and carbohydrates, for protecting the body from infection, and for maintaining a balance of minerals, vitamins, and hormones.

However, the liver can become damaged when breaking down toxic or infectious agents, although this damage typically does not impact its function for many years. Liver damage usually accumulates over time as a result of repeated exposure. At the same time, the liver is capable of regeneration. This makes it possible to donate a portion of the liver, since it can then grow back to its original size.

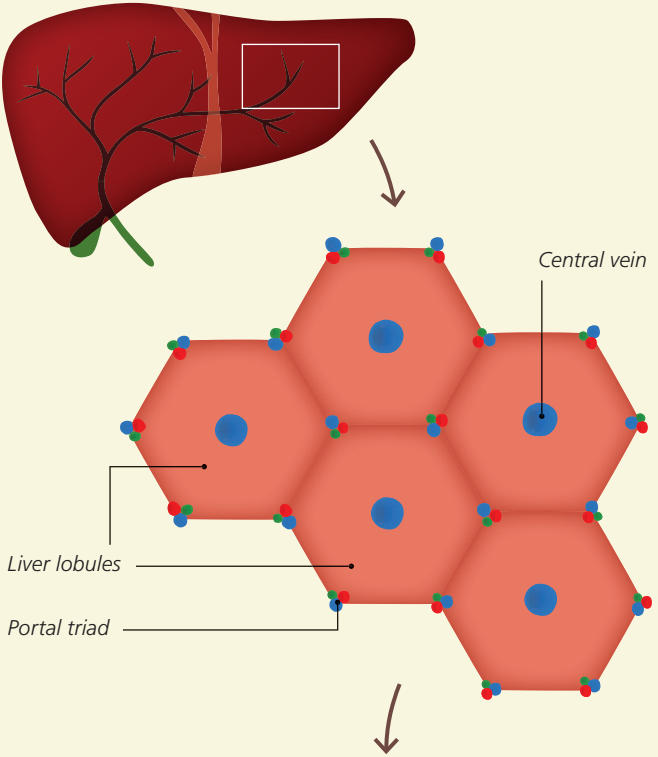


Functions of the liver

- **Metabolic and synthetic functions**
including proteins, carbohydrates, fats, clotting factors, vitamins, trace elements
- **Glandular functions**
including production of bile
- **Storage functions**
including glycogen, iron
- **Detoxification**
including harmful substances
- **Breakdown and excretion**
including various metabolic products, alcohol, medications

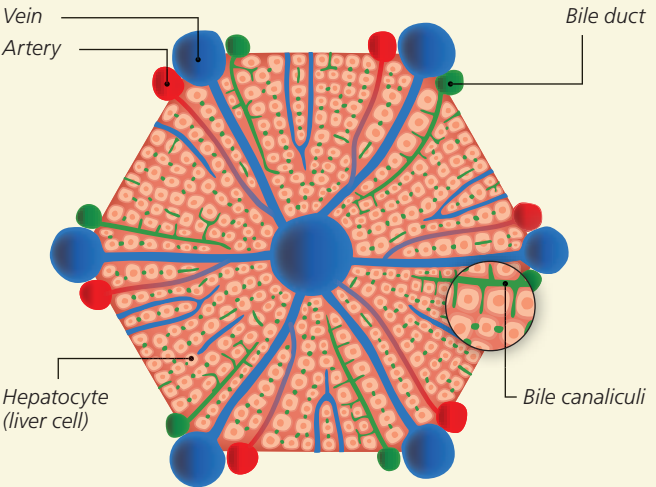


Structure of the liver, liver lobules, and bile ducts

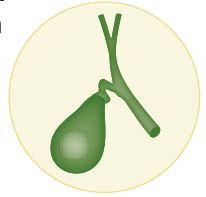


Liver lobule

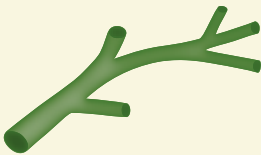
Blood vessels



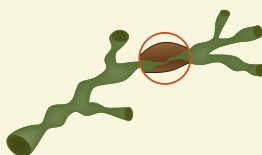
Lobules represent the smallest structural subunit from a functional perspective, and are comprised of highly-specialized hepatocytes (liver cells) arranged in a ring-like form. Very small blood vessels (sinusoids) cross through the lobules and allow the exchange of substances between the blood and the liver. The lobules also contain very small bile channels known as bile canaliculi. These channels surround the hepatocytes before merging into small bile ducts, which themselves merge to form larger bile ducts. Hepatocytes metabolize nutrients from the bloodstream not only in order to store them, but also to produce substances that are crucial for the body. In particular, they **produce 700–1,500 ml of bile per day**, which flows out through the bile canaliculi and bile ducts into the small intestine (duodenum) but also to the gallbladder, where it can be stored between meals. The gallbladder is located below the right lower lobe of the liver near the front of the abdomen. Following the ingestion of food, it secretes bile by contraction, which then travels through the bile duct system into the small intestine, where it promotes the digestion of food, particularly of fats.



When the small bile ducts are deformed and damaged by inflammation, diseases such as primary biliary cholangitis (PBC) may develop.



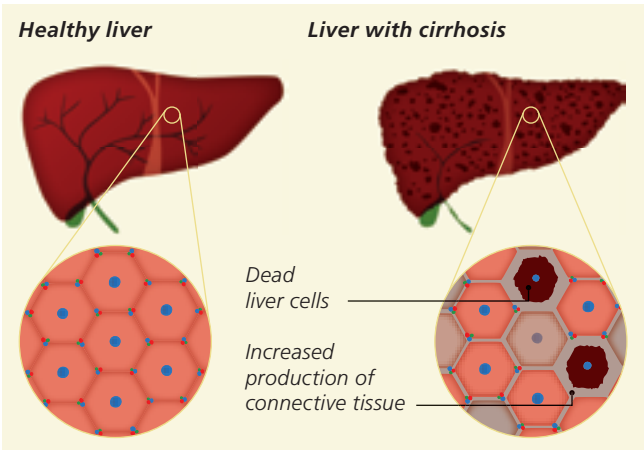
*Normal bile ducts
in the liver*



*Structure of a bile duct
damaged by inflammation*

What is primary biliary cholangitis?

Primary biliary cholangitis (PBC, formerly known as primary biliary cirrhosis) is a chronic, progressive, autoimmune disease of the liver that begins with inflammation of the small bile ducts in liver tissue. This inflammation is not triggered by bacteria or viruses, but rather by the patient's own immune system (white blood cells) which target the patient's body (hence the term "auto-immune"). **Both genetic and environmental factors are thought to be causes of the disease. This inflammation leads to progressive destruction of the small bile ducts and also attacks the surrounding liver cells.**



The progression of inflammation and the resulting formation of scar tissue (fibrosis) are subdivided into four stages, although the length of each stage is not known. The final stage of liver destruction is called **cirrhosis** (the source for the original name of PBC). However, there are also a number of other causes of cirrhosis aside from PBC (for example liver damage caused by viral infection or alcoholic or non-alcoholic fatty liver disease).

How common is the disease?

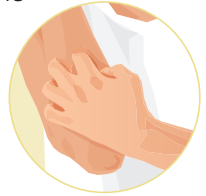The frequency (prevalence) of PBC is estimated to be 35 per 100,000 in the general population, with an annual rate of about 5 newly diagnosed cases of PBC per 100,000 people (incidence). PBC is thus considered to be a rare disease. Women account for 80–90% of cases, with only 10–20% among men. The disease usually starts between the ages of 40 and 60, although the youngest patient with a confirmed case of PBC was 15 years old. An increase in the number of PBC cases has been observed in recent years, especially in Europe and the United States, although the reason for this increase is unclear. Women in Europe or the United States with a mean age of 50 are at the highest risk of developing PBC.

Does PBC shorten life expectancy?

Although the risk of liver failure is 25% in patients with **untreated** PBC, the progression of liver damage can be greatly delayed or even stopped using the medications currently available. If PBC is detected early enough and patients respond well to treatment with medications – as is the case for about 75% of patients – life expectancy remains normal. In the rare cases of patients who develop cirrhosis with liver failure or cancer despite treatment, it may be possible to cure PBC by liver transplantation.

What are the signs of PBC?

PBC is often not detected for many years. The first hints of PBC are frequently elevated levels of certain liver enzymes observed during a routine blood test by a primary care physician. The initial sign of PBC may be mild, moderate, or even severe itching (pruritus). This itching is primarily felt at night and often affects the arms, back, and lower legs. It may be intensified by heat (such as in bed) or by dry air (for example when heating an indoor space in winter). Major fatigue, decreased strength, or an uncomfortable sensation of pressure in the right upper abdomen may also be initial signs of the disease (see table 1). Dry mucous membranes caused by a reduced production of tears and saliva represent a group of symptoms known as sicca syndrome. Another typical sign of PBC is yellowish-grey deposits of fat below the skin around the inner corners of the eyelids (called xanthelasma, see page 20). Joint symptoms may also be observed that are similar to those of rheumatoid



arthritis, such as stiff fingers in the morning.

i

Autoimmune disease/ autoimmunity:

a pathological reaction by the immune system to the body's own tissues.

In patients with liver symptoms, the presence of certain autoimmune diseases such

as the thyroid disease Hashimoto's thyroiditis or rheumatic disorders (such as Sjögren's syndrome or rheumatoid arthritis) may be an indication of PBC, since these diseases frequently occur together with PBC (table 1).

PBC may also be initially detected after pregnancy. Approximately 1–2% of all pregnant women develop cholestasis of pregnancy. These women often experience cholestasis (build-up of bile) with severe itching (called intrahepatic cholestasis of pregnancy) that is triggered by their pregnancy during the last trimester. If the levels of bile in blood remain elevated or if itching does not subside (even if it decreases) after pregnancy, these are indications that PBC has developed.

Table 1: Factors pointing to PBC

- Primarily affects **women** ages 40 and above, and more rarely men (10–20%)
- **Itching** (arms, legs, back)
- **Fatigue**, exhaustion, decreased strength
- **Sensation of pressure** in the right upper abdomen
- **Dry eyes** and **mucous membranes** (sicca syndrome)
- **Fat deposits around the eyelids** (xanthelasma)
- **Yellow pigmentation** of the skin and the whites of the eyes (jaundice, icterus)
- **Joint symptoms** with morning stiffness, especially in the joints at the base of the fingers
- Presence of other **autoimmune diseases**
- Potential onset of symptoms during pregnancy




How do doctors diagnose PBC?

It used to be very difficult to diagnose PBC. Because the disease tended to be discovered during its final stage, it was originally called “primary biliary cirrhosis”. However, thanks to blood tests the disease can now be diagnosed in its early stages, before cirrhosis develops. For this reason, and to avoid unjustified stigma towards patients, the disease was renamed “primary biliary cholangitis” in 2015.

What are the main physical signs of the disease?

It is usually not possible to detect any abnormalities during the early stages of PBC, since signs like a yellow discoloration of the eyes (scleral icterus) or the skin are not yet present, and because the liver and spleen have not yet enlarged to a size that can be felt by the doctor. The only indication of the disease at this stage may be itching, especially on the arms and the legs. During more advanced stages, the liver may be enlarged, and signs of cirrhosis are observed at even later stages (see table 4).



Which blood tests are necessary?

The results of laboratory blood tests are important for diagnosing PBC (see table 2), as there may be elevated levels of enzymes in the bloodstream that indicate abnormalities in the bile ducts and cholestasis. These enzymes include alkaline phosphatase (AP) and gamma-glutamyl transferase (GGT or γ -GT). Blood cholesterol levels are also often elevated (hypercholesterolemia). If this group of findings is detected, blood serum is then tested for **anti-mitochondrial antibodies** (AMAs). These are antibodies that circulate in the bloodstream and target specific components of the cellular organelles that produce energy (mitochondria). However, these antibodies are neither the cause of PBC nor are they responsible for the severity of the disease. Nonetheless, when detected together with elevated AP and GGT levels, these antibodies confirm the diagnosis of PBC even in the absence of symptoms. This set of blood markers can be detected in more than 90% of PBC patients. However, AMAs

Antibodies: Soluble proteins called immunoglobulins (Ig) that are produced by specialized cells of the immune system. Immunoglobulins contain binding sites that are highly specific for other protein components. These components may include surface structures on foreign cells, bacteria, fungi, viruses, pollen, medications, or parts of food. After binding to a target like bacteria, the immunoglobulins can trigger additional processes that destroy the bacteria. In rare cases, the body can also produce antibodies that target its own structures; these are called autoantibodies (from the Greek $\alpha\upsilon\tau\omicron$ (auto-), meaning “self”). Immunoglobulins are subdivided into several different classes, and immunoglobulin M (IgM) in particular is elevated in PBC patients.



are absent in the other approximately 10% of PBC cases, which are termed AMA-negative PBC. For these patients, a liver biopsy is usually required for diagnosis (see below). Elevated levels of the liver enzymes alanine aminotransferase (ALT) and aspartate aminotransferase (AST) are typical indications of hepatocyte (liver cell) damage. These enzymes are usually only slightly or not elevated at the onset of PBC, since PBC begins with damage to bile duct cells. Increases in these parameters suggest that the disease is progressing.

Table 2: Typical blood test findings during the initial stage of PBC

- Elevated levels of alkaline phosphatase (AP) and gamma-glutamyl transferase (GGT, γ -GT)
- Slightly elevated levels of the aminotransferases ALT and AST
- Elevated cholesterol levels
- Detection of anti-mitochondrial antibodies (AMAs)
- Elevated immunoglobulin M (IgM) levels

A condition called jaundice (icterus) develops when the levels of the bile dye bilirubin increase in the blood during advanced stages of the disease. This is initially apparent in the eyes (scleral icterus) and later all over the skin. Because bilirubin can no longer be eliminated properly in bile, it is excreted in urine. This gives the urine a dark color, while stool becomes



lighter in color. The blood levels of bile acids are usually elevated in advanced stages of PBC. Liver function gradually deteriorates during the final stage of PBC (liver cirrhosis), which can be detected by decreases in protein concentration (albumin), platelets (thrombocytes), and blood clotting factors (prothrombin time).

What can be detected by ultrasound?

During the initial stage of PBC, there are no changes to the liver that can be detected using imaging procedures. Nonetheless, it is important to perform ultrasound imaging of the liver and the bile ducts in order to rule out other possible causes of cholestasis (especially gallstones, tumors, or narrowing of the ducts). Ultrasound examination is a safe and readily available method that does not emit radiation.

If PBC progresses to cirrhosis, ultrasound examination can be used to detect the typical presentation of cirrhosis, which is an irregular and bumpy surface of the liver (see figure on page 8) and water in the abdomen (ascites). The build-up of blood upstream of the liver causes the spleen to expand (splenomegaly). However, these abnormalities can also be observed in patients whose cirrhosis developed for other reasons. In other words, they are not specific for PBC.

Several non-invasive methods have become available in recent years that allow the degree of fibrosis in the liver to be measured (elastography), including an ultrasound-based method called Fibroscan[®]. This method allows the extent of liver damage to be evaluated even in the early stages of PBC, and provides insights into the prognosis of the disease. Fibroscan[®] is performed by placing a special ultrasound probe onto the skin over the liver. The probe then transmits a mechanical impulse toward the liver while measuring the expansion of the impulse wave through the liver. As more connective tissue is deposited in the liver (see figure on page 8), the tissue becomes stiffer and the impulse travels through the liver faster. If this speed reaches a certain level, the liver is assumed to have cirrhosis.

Does a liver biopsy need to be taken?

An ultrasound-guided liver biopsy (needle biopsy) is no longer generally recommended for confirming a diagnosis of PBC. If the laboratory test results are clear, a liver biopsy should be skipped in order to avoid potential complications (especially bleeding). It is currently possible for non-invasive techniques (e.g. Fibroscan®) to reliably evaluate the stage of PBC (meaning how far the connective tissue formation has advanced in the liver) or whether cirrhosis has already occurred. Nonetheless, a biopsy may be advisable in certain circumstances. These include patients with numerous indications of PBC but no evidence of AMAs (AMA-negative PBC), to rule out concurrent autoimmune hepatitis (see below) for patients whose liver enzymes (ALT and AST) are already very high even in an early stage, or to confirm the diagnosis for PBC patients who do not respond to treatment.

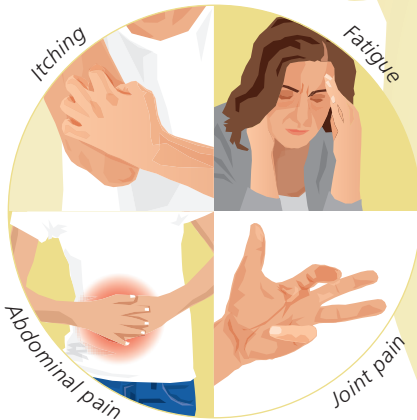Can genetic testing help predict PBC?

Comparisons of the DNA sequences between PBC patients and healthy controls have identified a number of genes that are linked to the development of PBC when mutated. Many of these genes are involved in regulating the body's immune system. Although each individual's predisposition to PBC appears to be genetically determined, the disease is not triggered by any one mutation. It is thus not (yet) possible to use a genetic test to detect or predict PBC.

How does PBC progress?

The disease often does not cause any symptoms during the early stages. Itching may be felt well before the initial diagnosis of PBC, but may also be absent until the final stage. More than half of all patients suffer from **persistent fatigue and exhaustion, which may also be accompanied by difficulty concentrating and remembering. Pain in the abdomen, muscles, or joints is reported less frequently.**

The symptoms of PBC may vary greatly and can impact patients' quality of life. More symptoms usually occur as the disease progresses.



What other conditions are typically associated with PBC?

Patients with PBC have up to a 50% chance of suffering from an additional autoimmune disease (see table 3). These diseases may include a condition called sicca syndrome, in which autoimmune inflammation reduces the ability of moisture-producing glands (such as the tear, salivary, and vaginal glands) to secrete moisture. Dry oral mucosa are more susceptible to cavities or fungal infection and are frequently associated with difficulty swallowing. The decrease in the production of tears often causes a sensation of having a foreign object in the eyes, along with burning, redness, sensitivity to light, swollen eyelids, and an inability to tolerate contact lenses. Dry eyes may also be more susceptible to infections since tears provide a defense against bacteria and viruses.

Hashimoto's thyroiditis is another disease that may be associated with PBC. In this condition, the body produces antibodies against thyroid tissue that attack the thyroid gland, leading to a decrease in its function. Approximately one-fourth of PBC patients also suffer from Raynaud's disease, which is when fingers or toes become painful and turn white/blue/red during cold weather. A more rare condition associated with PBC is restless legs syndrome, which is characterized by sensations of tingling and tension in the legs and results in a strong urge to move.

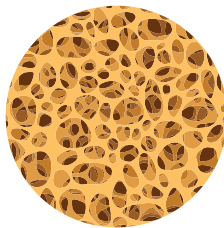
Fatty stool, vitamin deficiencies: In addition to dry mucous membranes, sicca syndrome can also lower the secretion of enzymes from the pancreas that cleave fats. This results in reduced breakdown of fats in the intestines, which causes the fats to be eliminated in stool, a condition called fatty stool (steatorrhea). Bile acids are also required for the uptake of fats and fat-soluble vitamins (vitamins A, D, E, and K) from the small intestine, meaning that the blockage of bile in the

Table 3: Autoimmune diseases that can accompany PBC. Common:

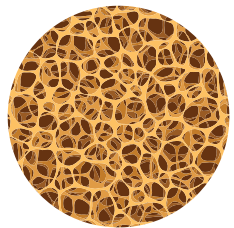
- Hashimoto’s thyroiditis = thyroid inflammation
- Sjögren’s syndrome (sicca syndrome) = dry mucous membranes
- Scleroderma = connective tissue disorder
- Autoimmune hepatitis = inflammation of the liver caused by immune reaction

liver results in too few bile acids in the intestines, which in turn leads to vitamin deficiencies. Vitamin A deficiency can trigger night blindness, while vitamin D deficiency leads to weakened bones (osteoporosis), and vitamin K deficiency can lead to blood clotting disorders. These vitamin deficiencies are only mild in most cases, meaning they cause few complications and rarely require treatment.

Weakened bones (osteoporosis): The weakening of bones (osteoporosis) is frequently a complication of or associated with PBC. The risk of developing osteoporosis increases as a result of the reduced uptake in fat-soluble vitamin D and as a result of liver inflammation. Since PBC primarily afflicts women, and since women may also develop osteoporosis due to menopause, it is difficult to clearly differentiate these two forms. Osteoporosis can be measured by X-ray examination (DEXA).

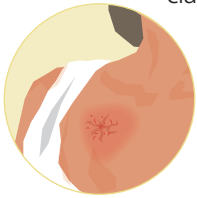


Normal bone



Osteoporosis

Skin changes: The fat deposits that can occur on the inside corners of the eyelids (xanthelasma) have already been described above. Small fatty nodules (xanthomas) may also form on the hands, feet, or buttocks. The skin and eyes usually become tinged with yellow (jaundice, see page 14), especially during advanced stages of the disease. When PBC progresses to the cirrhosis stage, the



classical signs of cirrhosis of the liver appear (see table 4). These signs include spider web-like red spots on the skin, especially on the chest (spider angioma), a more intense red color to the lips and tongue (“lacquered lips”), and a thinner appearance to the skin, especially in the face and forehead (“paper money skin”).

What is cirrhosis of the liver and what are its implications?

Liver cirrhosis means that the liver tissue has been destroyed and replaced by scar tissue and connective tissue. This restricts the amount of blood that can flow through the liver, which must then bypass the liver in a process called collateral circulation. These bypasses may lead to varicose veins in the esophagus and/or stomach (esophageal varices/gastric varices) which can sometimes cause major bleeding. The back-up in blood flow in the stomach wall may cause low-level but continuous blood loss. Fluid retention in the abdomen (ascites) and cognitive dysfunction (hepatic encephalopathy) may further complicate the clinical presentation. During cirrhosis, the liver produces much less protein and fewer clotting factors. These low levels of protein lead to edema (such as swollen lower legs) and an increased risk of bleeding. In the advanced stages of PBC, kidney function among others deteriorates as a consequence of the ascites and exacerbated by the protein deficiency, a condition termed hepatorenal syndrome. Bacterial infections, especially in the abdominal fluids, or bleeding from the varices, are

frequent triggers for an acute deterioration of the patient's condition leading to acute kidney failure and to exacerbation of the encephalopathy. The muscle atrophy typically affects the arms and the legs (sarcopenia) over the course of the disease.

Table 4: Complications of cirrhosis of the liver

- Bleeding from esophageal or gastric varices, occasionally also from ulcers in the stomach or duodenum
- Ascites
- Cognitive dysfunction triggered by liver disease (hepatic encephalopathy)
- Clotting disorders with higher risk of bleeding
- Edema (such as swollen lower legs) resulting from low levels of protein
- Kidney dysfunction caused by liver cirrhosis (hepatorenal syndrome)
- Greater susceptibility to infections
- Muscle atrophy in the arms and legs (sarcopenia)
- Liver cancer (hepatocellular carcinoma)

Are PBC patients at a higher risk of cancer?

The risk of developing liver cell cancer (hepatocellular carcinoma, HCC) is higher, especially in the cirrhosis stage. Approximately 3 in every 1,000 patients with (advanced) PBC develop HCC; men are at a greater risk than women. Ultrasound examinations of the liver must be performed by an experienced doctor and levels of AFP (alpha-1 fetoprotein) should be measured every six months in order to ensure an early diagnosis of HCC.

i

Carcinoma: A subgroup of malignant cancers that originate from epithelial tissue. Hepatocellular carcinoma (= liver cell cancer, abbreviated HCC) is a malignant form of cancer that originates in liver cells and frequently develops in patients with liver cirrhosis.

AFP is a protein that is usually produced at high levels in HCC and is used as a cancer marker for HCC.

How is PBC treated?

When treating PBC, it is important that treatment focuses not only on the liver disease itself, but also on any other conditions that may accompany the disease (such as other autoimmune diseases, see page 19). Should any other conditions be present, their treatment must be incorporated into the overall treatment strategy.

The goal of PBC treatment is to slow or stop the progression of the disease. If PBC has already advanced into the cirrhosis stage or if hepatocellular carcinoma (HCC) has developed, liver transplantation may actually provide a cure for PBC. Although the disease does relapse after transplantation in some patients, these cases are generally rare. Patients' quality of life can be positively impacted by treating the symptoms of the disease.

The most crucial risk factors for developing a severe form of PBC are male gender, young age (< 45 years old), an advanced stage of the disease at diagnosis, and poor response to treatment with ursodeoxycholic acid (see page 24). Patients with these risk factors should seek treatment at specialized centers that offer a wider range of treatment options.


Which medications are used to treat PBC?

Medications (see table 5) are prescribed as soon as possible, meaning immediately after the diagnosis has been made. This treatment initially involves the bile acid ursodeoxycholic acid (UDCA), which is usually only present at low concentrations in human bile. The dose of UDCA is 13–15 mg/kg body weight per day. It can be divided into two to three doses over the course of the day or taken as a single dose in the evening.

Treatment is life-long and should not be discontinued even after liver transplantation is performed as it reduces the risk of recurrence, and is current practice in most centers. UDCA may cause diarrhea in rare cases, but it is usually possible to take this medication for many years with no side effects. Although only limited experience is available on the use of UDCA during pregnancy, it is still generally recommended that UDCA be taken continuously by patients with PBC. Therefore, patients who are pregnant or breast-feeding should talk with their doctor about taking UDCA during this time.

Treatment with UDCA is associated with a high probability (about 75%) of improvement or normalization of blood test levels, especially for parameters associated with biliary tract inflammation. Moreover, UDCA has been shown to improve not only laboratory test findings, but also the results of microscopic (histology) liver tissue tests. **A normal life expectancy can be expected if PBC is detected at an early stage and if liver enzyme levels normalize with UDCA treatment.**

There is some debate on the effects of UDCA on the symptoms of PBC, meaning fatigue and itching. The treatment of these two symptoms often requires patience and persistence (see below). Nonetheless, UDCA treatment is considered to be mostly beneficial.



Response to UDCA treatment should be verified by laboratory testing after no later than 12 months. If specific blood test parameters (especially AP and bilirubin) do not drop below a certain level, the response to UDCA is considered to be insufficient or absent, and requires more intensive treatment by specialists.

One promising alternative is the combination of UDCA with an additional (synthetic) bile acid called obeticholic acid (OCA), which was approved in Europe in December 2016 for PBC patients who do not adequately respond to UDCA. Over half of the patients who originally did not respond or did not adequately respond to UDCA responded to this combination. OCA may only be prescribed at reduced doses to patients known to have advanced disease with cirrhosis (Child-Pugh classes B and C). The dose should be tailored to the degree of liver function in order to avoid severe complications such as acute liver failure. OCA is typically tolerated very well by patients without known advanced cirrhosis of the liver. The primary side effect is a potential triggering or worsening of itching, which may require the dose of the medication to be reduced or the medication to be stopped altogether.

Other drugs that interfere with bile acid metabolism through PPAR α receptors are currently being tested as second-line therapy. Although these drugs were previously not approved for PBC, they are now mentioned in the current guidelines. Ask your doctor for more information about these medications.

Table 5: Medications used to treat PBC

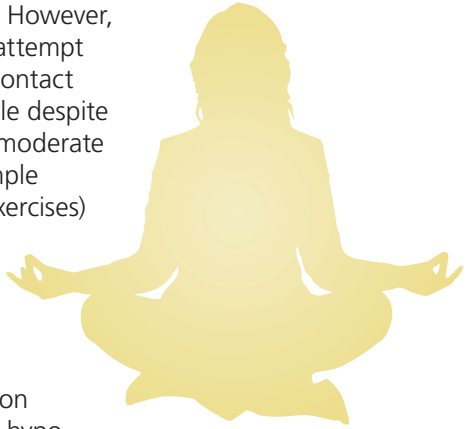
- Ursodeoxycholic acid (UDCA): 13–15 mg/kg body weight per day
- Start of treatment: immediately after diagnosis
- Length of treatment: life-long or until liver transplantation
- In cases of insufficient response to UDCA: combination treatment with obeticholic acid (OCA)

How can the symptoms of the disease be reduced?

Treating PBC with UDCA usually does not significantly alleviate the symptoms of the disease, which patients often perceive as being very unpleasant. One initial requirement for effective treatment is the systematic documentation of the symptoms (using standardized questionnaires), which should be repeated at regular intervals.

A number of medications are available to treat the symptom of itching, which may be very severe in some situations. The skin should be kept moist using natural skin care products. A cold shower may (temporarily) alleviate itching, since it is frequently exacerbated by warmth. A comprehensive allergy test should be performed to rule out other possible causes of the itching. In extreme cases, alternative forms of treatment may be attempted at specialized centers, including a type of dialysis called albumin dialysis, using a nasal probe to drain bile, or whole-body UVB light treatment (phototherapy). If none of these treatment attempts work, the option of liver transplantation should be discussed. Itching typically subsides within the first 24 hours after the transplantation.

It is difficult to treat fatigue and exhaustion since no medications are currently available for these symptoms. However, patients should still attempt to engage in social contact and an active life style despite the fatigue. Mild to moderate movement (for example walking, balanced exercises) may have beneficial effects on overall well-being. It is crucial that other potential causes of fatigue and exhaustion be ruled out (such as hypothyroidism or a sleep disorder caused by itching). In contrast to itching, fatigue usually persists after liver transplantation.



In cases of dry eyes and dry mucous membranes (sicca syndrome, see above), artificial tears and saliva should be used or medications that promote secretion should be taken. If the production of pancreatic enzymes that cleave fat is also reduced (fatty stools), the fat content in the diet should be reduced to 40–50 g per day, and easily digestible fats (such as those in margarine and oils) should be preferred. If these changes are not enough, pancreatic enzyme tablets will need to be taken before each meal. A balanced diet combined with regular outdoor physical activity is crucial for preventing osteoporosis, which is a common early complication of PBC (see table 6).

Table 6: Treatment of osteoporosis resulting from PBC

- Outdoor physical activity
- Balanced diet
- Vitamin D₃, calcium
- Medications that promote bone growth

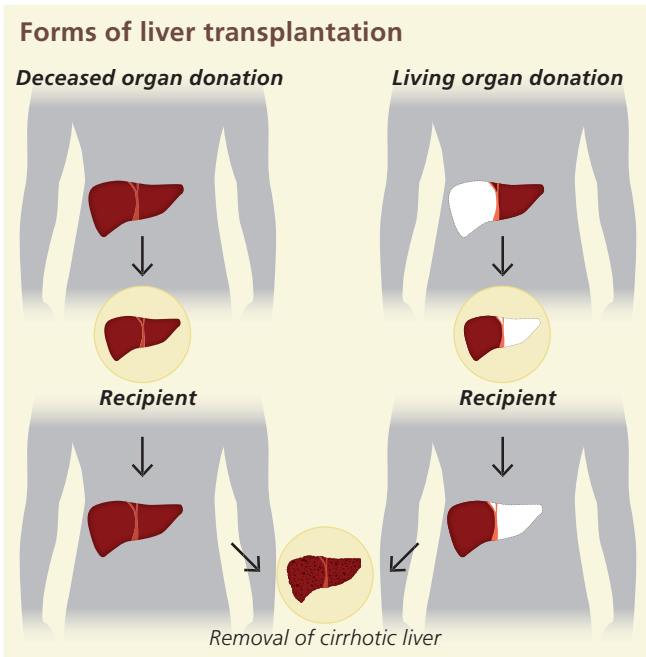
Only take calcium or vitamin D if there are confirmed indications of a deficiency (by blood test) or if osteoporosis has already begun (X-ray measurement of bone density by DEXA). If bone density drops below a certain level (T-score), treatment should be started using medications that promote bone growth.

Cholestasis may lead to reduced uptake of the fat-soluble vitamins A, D, E, and K from the intestines (see page 10). However, a genuine vitamin deficiency is exceedingly rare and usually only occurs together with sustained jaundice or liver cirrhosis. Vitamin supplementation must be performed by injection, since the intestines will also not be able to absorb vitamin tablets.

When is liver transplantation required?

Liver transplantation represents the most feasible option for patients with advanced disease whose liver function can no longer be maintained, for patients with severe complications, or for patients with uncontrollable itching. Although liver transplantation represents one of the most major forms of surgery, the procedures are now well-established and have a very high success rate. If the disease has indeed progressed this far, treatment will need to be carried out at a transplantation center (in a university hospital). It will first be necessary to perform a number of tests to determine eligibility for surgery. The survival rate of PBC patients after transplantation

is typically very high. PBC relapses after transplantation in about 10–20% of patients, who then require retreatment. It is thus recommended that treatment with UDCA also be continued after transplantation.



During liver transplantation, the recipient receives the liver from an organ donor. This is performed by first removing the diseased liver and then transferring the donated liver. Other variations also exist, including split-liver transplantation and liver transplantation from a living donor.

What is a PBC overlap or variant syndrome?

For approximately 10% of PBC patients, there is evidence from both laboratory results (greatly elevated liver enzymes, ALT and AST, and immunoglobulin G) and from microscopic examination of liver tissue that actually suggests that the patient may also have another autoimmune liver disease together with PBC (autoimmune hepatitis). In rare cases, signs of autoimmune hepatitis may suddenly develop years after the diagnosis of PBC. These mixed conditions are called an overlap syndrome (also known as a variant syndrome). This phenomenon illustrates why blood tests should be performed every six months even for patients on successful UDCA therapy. If an (additional) autoimmune hepatitis is suspected, a liver tissue biopsy will have to be taken in order to confirm the diagnosis.

Combination treatment with UDCA and a corticosteroid (such as budesonide) is recommended for patients afflicted with an overlap syndrome. After liver enzyme levels have normalized, the immunosuppressant drug azathioprine is prescribed as maintenance therapy, while the corticosteroid therapy is slowly tapered. It is usually necessary to continue taking the combination of azathioprine (possibly at a reduced dose) and UDCA indefinitely. In rare cases, azathioprine can be successfully discontinued many years later. Other immunosuppressants are available for patients who do not tolerate azathioprine.

**i**

Immunosuppression: A treatment strategy that addresses inflammation or transplant rejection by suppressing the immune system. Pursuing this goal also poses several risks, including infections (more frequent) and the potential development of malignant cancer (rare). The medications used for this strategy belong to a group called immunosuppressants.

Summary

- Primary biliary cholangitis is a **chronic autoimmune disease** of the bile ducts.
- It initially attacks the **small bile ducts but can transition to liver tissue**, which gradually leads to cirrhosis of the liver.
- Thanks to improved diagnostic tests, it is now possible to detect the disease **at an early stage, which can have very beneficial effects on the prognosis and course of the disease.**
- The primary medication used to treat PBC is ursodeoxycholic acid (sometimes in combination with obeticholic acid). **This treatment is initiated immediately after diagnosis and continues life-long. UDCA should also be continued after transplantation.**
- For the majority of patients, ursodeoxycholic acid improves their blood test levels and their life expectancy. Patients whose PBC is diagnosed at an early stage and who respond well to treatment have a normal life expectancy.
- Liver transplantation is performed if the disease has **progressed to liver cirrhosis with complications, if hepatocellular carcinoma develops, or if itching becomes uncontrollable.**
- **The outcomes from liver transplantation are very good and are constantly improving.**

FALK FOUNDATION e.V.



Leinenweberstr. 5
79108 Freiburg
Germany

U82EPBC 1-10/2019 POP